Accepted Manuscript

Title: An extranodal histopathological analysis of idiopathic multicentric Castleman disease with and without TAFRO syndrome

Author: Nozomu Kurose

PII: S0344-0338(18)31509-7
DOI: https://doi.org/10.1016/j.prp.2018.12.025
Reference: PRP 52290

To appear in:

Received date: 30 October 2018
Revised date: 30 November 2018
Accepted date: 24 December 2018

Please cite this article as: Kurose N, An extranodal histopathological analysis of idiopathic multicentric Castleman disease with and without TAFRO syndrome, *Pathology - Research and Practice* (2018), https://doi.org/10.1016/j.prp.2018.12.025

An extranodal histopathological analysis of idiopathic multicentric Castleman disease with and without TAFRO syndrome

Nozomu Kurose

Kanazawa Medical University, k9696path@gmail.com, 920-0293

ABSTRACT

Thrombocytopenia, anasarca, fever, renal failure or reticulin fibrosis, and organomegaly (TAFRO) syndrome, a poor prognostic clinical condition showing similar histopathological findings to idiopathic multicentric Castleman disease (iMCD), has been reported in Japan. In our previous report, a clinicopathological analysis was performed on 70 nodal cases of iMCD with/without TAFRO. iMCD is classified into three types based on histopathology: (i) plasmacytic (PC), (ii) mixed, and (iii) hypervascular (hyperV). In this report, extranodal histopathological changes of iMCD with/without TAFRO were analyzed. Regarding the kidney pathology, we observed the proliferation of mesangial cells with positive staining of interleukin-6 (IL-6), consistent with membranoproliferative glomerulonephritis, in two cases of iMCD with TAFRO. The number of megakaryocytes per high-powered fields was not significantly different between iMCD cases with and without TAFRO. In conclusion, extranodal lesions of iMCD with/without TAFRO showed various interesting

histopathological findings. These lesions may therefore be related to the clinical condition of TAFRO. Obtaining further knowledge about TAFRO will require the observation of nodal as well as extranodal lesions.

Key words: idiopathic multicentric Castleman disease; extranodal lesion; membranoproliferative glomerulonephritis; TAFRO syndrome.

INTRODUCTION

Multicentric Castleman's disease (MCD) causes overproduction of interleukin-6 (IL-6) and shows various clinical conditions, such as fever, malaise, systemic lymphadenopathy, and multiple organ failure [1]. It also indicates various laboratory abnormalities, such as hypergammaglobulinemia, thrombocytosis, anemia, and elevation of C-reactive protein levels [1].

It is well-known that Human herpes virus-8 (HHV-8)-related MCD occur mainly in patients suffering from human immunodeficiency virus (HIV) infection. However, idiopathic MCD (iMCD) cases with HIV-negative and HHV-8-negative have been reported in Japan [2-4]. In addition, Fajgenbaum et al. [5] have recently described the presence of HIV-negative and HHV-8-negative iMCD in Western countries. They classified iMCD into three types based on histopathology: (i) plasmacytic (PC), (ii) mixed, and (iii) hypervascular (hyperV).

In 2010, the report from Takai et al. [6] showed three cases termed TAFRO syndrome

displaying several common clinical symptoms, such as thrombocytopenia, anasarca, fever, renal failure or reticulin fibrosis, and organomegaly. The lymph node (LN) obtained from the TAFRO syndrome patients was histopathologically similar to hyaline-vascular type of CD, but they were clinically quite different from typical iMCD. Despite these findings, Fajgenbaum, et al. [5] later classified this characteristic syndrome as one phenotype type for MCD according to the histopathological similarity of LN lesions in iMCD.

In our previous report [7], a clinicopathological analysis was performed on 70 nodal cases of iMCD with/without TAFRO. The tissue of LN in PC-type histopathologically showed a characteristically atrophic lymphoid follicle (LF) and mild vascular proliferation at the germinal center (GC). Also, at the interfollicular area, a sheet-like infiltration of plasma cells was observed but vascular proliferation was very sparsely seen. In the mixed-type, atrophic to hyperplastic LF was formed, and glomeruloid vascular proliferation (GVP) was found in GCs. A dense proliferation of high endothelial venules without hyalinization was recognized in the interfollicular region, and plasma cell infiltration was observed around the blood vessels. A marked atrophic change of LF was observed in hyperV-type, and GVP completely replaced with GC. Furthermore, we revealed markedly high endothelial venules at the interfollicular area, and that plasma cell infiltration was found sparsely.

To clarify the clinicopathological findings of iMCD with/without TAFRO, it is necessary to observe systemic histopathological changes in not only lymph node tissue but also in other

tissue compartments. In this original contribution, we analyzed extranodal histopathological changes of iMCD with/without TAFRO.

MATERIALS AND METHODS

Clinically diagnosed cases as TAFRO syndrome with/without CD was registered by Retrospective Multicenter Clinical Study of TAFRO Syndrome (UMIN000011809). Among these cases, 92 cases of LN specimens were collected (3 unicentric CD, 88 iMCD, and 1 HHV-8-related MCD). Cases were included that had both lymph node histopathology consistent with iMCD as well as histopathological changes in extranodal lesions We excluded out well-defined malignancies, autoimmune diseases, and infectious diseases from this study [5]. Based on diagnostic criteria in Japan, certified clinicians (Drs. YM, SF, and HK, co-authors) have confirmed clinical diagnosis in each case as iMCD with/without TAFRO [8]. All cases for iMCD with TAFRO also corresponded to Iwaki's diagnostic criteria [9]. By contrast, we defined iMCD without TAFRO as demonstrating histopathological features of MCD without fulfilling the diagnostic criteria for TAFRO. This study was received the institutional ethics committee's approval from Kanazawa Medical University (No. 2063).

All tissue samples were embedded in paraffin after 10% neutral buffered formalin fixation. The sections were stained with hematoxylin and eosin (H&E), Gitter stain to evaluate the fibrosis grade, and periodic acid-methenamine silver stain (PAM) to evaluate renal lesions.

The degree of reticulin fibrosis was evaluated according to the myelofibrosis grading system proposed by Thiele et al. [10]. All bone marrow cases were evaluated by needle biopsy specimen. Standard 4 μm-thick sections were cut from all samples. Immunostaining was

performed according to previously described methods [11-15]. All immunostains were performed automatically (BenchMark GX, Ventana Medical System, Tucson, AZ, USA), and the antigen-antibody complex was visualized with 3,3'-diaminobenzidine solution. An anti-human IL-6 monoclonal antibody (clone 10C12, 1:50 dilution; Leica Microsystems, Wrtzlar, Germany) was immunostained with incubation for 30 min at 37 °C [11-15]. Immunostaining for IL-6 was evaluated only in kidney specimens.

PRISM software program, ver. 6 (Graph Pad Software, La Jolla, CA, USA) was used for all statistical analyses. The Mann-Whitney U test was used to compare histopathological data among iMCD with/without TAFRO. $P < 0.05$ was considered to be significant [11-15].

RESULTS

After excluding patients with the diseases described in the exclusion criteria, a total of 70 iMCD cases, including 37 with TAFRO and 33 without TAFRO cases, were ultimately selected. Among these 70 cases, we examined extranodal histopathological changes present in kidney (n = 2), bone marrow (n = 17), lung (n = 5), skin (n = 3), and thymus (n = 2). The number of each organs were summarized in Table 1.

Extranodal lesions

Kidney

Renal biopsy specimens from two patients with iMCD with TAFRO (one PC-type and one mixed-type) were evaluated. Both cases showed histopathological changes indicative of membranoproliferative glomerulonephritis (MPGN). The glomeruli showed lobular architectures with increased numbers of mesangial cells and mesangial matrix (Fig. 1A). At the periphery of the glomerulus, a double contour was observed (Fig. 1B). No proliferation of vascular endothelial cells was noted. Immunohistochemical staining for IL-6 revealed positivity for proliferated mesangial cells, visceral epithelial cells, Bowman's epithelial cells and tubular epithelial cells (Fig. 1C). The number of mesangial cells per glomerulus in iMCD with TAFRO was significantly higher than in normal kidney control (76.5 ± 13.0 versus 36.0 ± 9.39, $P < .0001$).

Bone marrow

Bone marrow biopsy specimens from patients with iMCD with TAFRO (PC-type; n = 1, mixed-type; n = 13) and iMCD without TAFRO (PC-type; n = 2, mixed-type; n = 1) were evaluated. The cellularity of iMCD with TAFRO was variable; hypocellular (n = 1), normocellular (n = 9), or hypercellular (n = 4, Fig. 2A). The cellularity of iMCD without TAFRO was normocellular (n = 2) and hypercellular (n = 1). The number of megakaryocytes/HPF was not significantly different between iMCD with TAFRO (10.9 ± 10.0) and iMCD without TAFRO (8.7 ± 9.8). Atypical megakaryocytes were found in 50% of the iMCD with TAFRO cases and 33.3% of the iMCD without TAFRO cases (Fig. 2B). The fibrosis grade of iMCD with TAFRO was MF0 (n = 3), MF1 (n = 7), and MF2 (n = 4), while that of iMCD without TAFRO was MF0 (n = 3). The fibrosis grade in iMCD with TAFRO was significantly higher than in iMCD without TAFRO (P = 0.0256). Plasmacytosis was found both iMCD with TAFRO and iMCD without TAFRO.

Lung

Lung biopsy specimens from five patients with PC-type iMCD without TAFRO were evaluated. Peribronchial and periarterial chronic inflammation accompanied by the formation of LFs was observed (Fig. 3A). In some areas, nodular stromal fibrosis with lymphocyte

aggregation were formed (Fig. 3B). Fibrous changes in the visceral pleura and alveolar septum, obliterative phlebitis, storiform fibrosis, eosinophil infiltration was not seen, but dense plasma cell infiltration without fibrosis was observed in the alveolar septum.

Skin

Skin biopsy specimens from two patients with mixed-type iMCD with TAFRO and one patient with mixed-type iMCD without TAFRO (mixed-type; n = 1) were evaluated. Glomeruloid hemangiomas were observed in all three cases.

Thymus

Thymic biopsy specimens from two patients with the mixed-type iMCD with TAFRO were evaluated. Histologically, thymic hyperplasia (epithelial and lymphocytic) with septal fibrosis was observed. Although mild vascular proliferation was noted among the thymic tissues, no characteristic histology of hyaline vascular type CD was noted.

DISCUSSION

In this study, extranodal lesions—including those of the kidney, bone marrow, lung, skin, and thymus—of iMCD cases with and without TAFRO were analyzed clinicopathologically.

Interestingly, the renal lesions associated with iMCD with TAFRO showed histopathological findings of MPGN. Zhang et al. [16] reported two cases of iMCD showing MPGN, but neither met the diagnostic criteria for TAFRO syndrome. In contrast, Tanaka et al. [17] reported MPGN-like lesions complicated with TAFRO syndrome with serum IL-6, VEGF, and Cre elevation. Noda-Narita et al. [18] also showed diffuse lobular endocapillary proliferative glomerulonephritis with endothelial swelling and the infiltration of monocytes and neutrophils. Similarly, Ozeki et al. [19] revealed thrombotic microangiopathy-like lesions with lobular pattern, mesangiolysis, double contours of the glomerular basement membranes and marked endothelial swelling. We showed for the first time that mesangial cells are positive for IL-6 immunostaining in renal lesions associated with TAFRO syndrome.

Matsumura [20] examined distribution of IL-6 in human proliferative glomerulonephritis, immunohistochemically. IL-6 is localized in the mesangial region, visceral epithelial cells, Bowman's epithelial cells, cellular crescent and tubular epithelial cells. Furthermore, IL-6 plays a role as an autocrine regulator of mesangial cell proliferation, and expression of IL-6 has been shown to be a good indicator of glomerular cell proliferation [21-22]. The proliferation of mesangial cells accompanied by the high expression of IL-6 was presumed to cause secondary

MPGN, renal dysfunction with increased serum Cre level, and anasarca. If renal dysfunction is observed in iMCD patients, we need to consider performing a renal biopsy.

Audia et al. [23] showed that splenic macrophages phagocytosed platelets with the production of antiplatelet antibodies, resulting in thrombocytopenia. Even in the presence of TAFRO syndrome, the production of platelet-associated IgG has been reported [24], which is presumed to cause hypersplenism and thrombocytopenia. Increases in the numbers of atypical megakaryocytes and reticulum fibers are thought to be reactive changes accompanying thrombocytopenia. In the present study, we observed cases in which reticulin fibrosis was not noticeable in the bone marrow of patients with TAFRO syndrome. Therefore, we should consider not only the presence of reticular fibrosis but also increases in the numbers of megakaryocytes and nuclear atypia as the features of TAFRO syndrome.

No pulmonary lesions were examined in cases of iMCD with TAFRO in this study. In some cases of iMCD without TAFRO, characteristic pulmonary lesions, such as lymphoplasmacytic proliferation mainly in the alveolar area adjacent to the perilymphatic stromal area as described by Terasaki et al. [25], were identified. For pulmonary lesions of iMCD, we should carefully look for dense plasma cell infiltration without fibrous thickening in the alveolar septum. Clinicopathological examinations of the lung lesions in iMCD with TAFRO are expected in future studies.

In conclusion, extranodal lesions of iMCD patients with and without TAFRO revealed

various interesting histopathological findings, suggesting that these lesions may be related to the clinical condition of TAFRO. Obtaining further knowledge about TAFRO will require the observation of nodal as well as extranodal lesions.

ACKNOWLEDGEMENTS

The authors would like to thank the members of the Castleman-TAFRO research team (Yoshizaki team and Masaki team) who provided the cases and clinical data. The authors would also like to acknowledge all of the investigators, including Drs. Tsutomu Sato (Sapporo Medical University), Keiki Kawakami (Suzuka General Hospital), Masaya Mukai (Sapporo City General Hospital), Sae Wada (Okayama Rosai Hospital), Hiroshi Yamamoto, Yoko Ozawa (NHO Shinshu University), Jun Konishi, Kazutaka Sunami (NHO Okayama Medical Center), Yoko Okitsu (Tohoku University), Shin-ichi Nureki (Oita University), Hiroatsu Iida (NHO Nagoya Medical Center), Keigo Setoguchi (Tokyo Metropolitan Komagome Hospital), Makoto Ide (Takamatsu Red Cross Hospital), Daisuke Wakasugi (Kurume University), Koji Nikkuni (Niigata City General Hospital), Shigeki Hatanaka (Imamura Byoin Bun-in Hospital), Masao Hagihara, Morihiro Inoue (Eiju General Hospital), Yoshitaka Sunami (Juntendo University Shizuoka Hospital), Nobuhiko Nakamura (Gifu University), Kenji Nara (Seirei Mikatahara General Hospital), Sachiko Ando (Teine Keijinkai Hospital), Masakuni Tanimizu (Tottori Municipal Hospital), Tadashi Koike (Nagaoka Red Cross Hospital), Keiko Yamagami

(Osaka City General Hospital), Yuto Mimura, Toshiro Ito (NHO Matsumoto Medical Center), Akio Saito (Fujioka General Hospital), Yoshihiko Raita (Okinawa Prefectural Chubu Hospital), Yusuke Takagi (Toyota Kosei Hospital), Hisao Nagoshi (Kyoto Prefectural University), Hiroki Tsutsumi, Naoki Kimura, Tatsuhiko Shinohara, Masaru Ejima (Tokyo Medical and Dental University), Toshimitsu Ueki (Nagano Red Cross Hospital), Ken Mizuguchi (Kariya Toyota General Hospital), Takayuki Fujio (Ibaraki Prefectural Central Hospital), Saki Minoda (Tenri Hospital), Kiyoshi Okazuka, Nobuhiro Tsukada (Japanese Red Cross Medical Center), Sachiko Suzuki, Mitsutoshi Kurosawa (NHO Hokkaido Cancer Center), Hiroto Tsuboi (Tsukuba University), Toru Murakami (Japanese Red Cross Kyoto Daini Hospital), Masato Arao (Saitama Medical University), Masanori Kobayashi (Osaka City University), Kimio Morita (Dokkyo Medical University Saitama Medical Center), Marie Nakashima (Chutoen General Medical Center), Seiichiro Yoshizawa (Tokyo Medical University), and Takeki Mitsui, Norifumi Tsukamoto, Akihiko Yokohama, (Gunma University) at the institutions participating in this study.

CONFLICTS OF INTEREST

None.

AUTHOR CONTRIBUTION

NK and SY participated in the conception of the study and writing of the manuscript. KM, MK, AS, XG, SN, SF, HK, YM, KT, SA, MK, SN and MK performed the clinical imaging and/or pathological/ /immunohistochemical interpretation of this lesion. All of the authors have read and approved the final manuscript.

REFERENCES

1. Kawabata H, Kadowaki N, Nishikori M, et al. Clinical features and treatment of multicentric Castleman disease: a retrospective study of 21 Japanese patients at a single institute. J Clin Exp Hematop. 2013; 53: 69-77.

2. Iona EE, Baraboutis IG, Lekakis LJ, et al. Multicentric Castleman's disease in HIV infection: a systematic review of the literature. AIDS Rev. 2008; 10: 25-35.

3. Osborne J, Moore PS, Chang Y. KSHV-encoded viral IL-6 activates multiple human IL-6 signaling pathways. Hum Immunol. 1999; 60: 921-927.

4. Kojima M, Nakamura S, Nishikawa M et al. Idiopathic multicentric Castleman's disease. A clinicopathologic and immunohistochemical study of five cases. Pathol Res Pract. 2005; 201: 325-32.

5. Fajgenbaum DC, van Rhee F, Nabel CS. HHV-8-negative, idiopathic multicentric Castleman disease: novel insights into biology, pathogenesis, and therapy. Blood. 2014; 123: 2924-2933.

6. Takai K, Nikkuni K, Shibuya H,et al. Thrombocytopenia with mild bone marrow fibrosis accompanied by fever, pleural effusion, ascites and hepatosplenomegaly. Rinsho Ketsueki. 2010; 51: 320-325 (in Japanese).

7. Kurose N, Futatsuya C, Mizutani KI, et al. The clinicopathological comparison among nodal cases of idiopathic multicentric Castleman disease with and without TAFRO syndrome. Hum Pathol. 2018; (in press)

8. Masaki Y, Nakajima A, Iwao H, et al. Japanese variant of multicentric castleman's disease associated with serositis and thrombocytopenia--a report of two cases: is TAFRO syndrome (Castleman- Kojima disease) a distinct clinicopathological entity? J Clin Exp Hematop. 2013; 53: 79-85.

9. Iwaki N, Fajgenbaum DC, Nabel CS, et al. Clinicopathologic analysis of TAFRO syndrome demonstrates a distinct subtype of HHV-8-negative multicentric Castleman disease. Am J Hematol. 2016; 91: 220-226.

10. Thiele J, Kvasnicka HM. Hematopathologic findings in chronic idiopathic myelofibrosis. Semin Oncol. 2005; 32: 380-394.

11. Kurose N. Clinicopathological analysis between IgG4-related and non-IgG4-related diseases occurring in various organs and tissues: Re-evaluation of comprehensive diagnostic criteria and usefulness of interleukin-6 immunostaining. J Kanazawa Med Univ. 2016; 41: 76-85.

12. Noguchi H, Yamada S, Nabeshima A, et al. Depletion of apoptosis signal-regulating kinase 1 prevents bile duct ligation-induced necro-inflammation and subsequent peribiliary fibrosis. Am. J. Pathol. 2014; 184, 644–661.

13. Tasaki T, Yamada S, Guo X, et al. Apoptosis signal-regulating kinase 1 deficiency attenuates vascular injury-induced neointimal hyperplasia by suppressing apoptosis in smooth muscle cells. Am. J. Pathol. 2013; 182, 597–609.

14. Nawata A, Noguchi H, Mazaki Y, et al. Overexpression of peroxiredoxin 4 affects intestinal function in a dietary mouse model of nonalcoholic fatty liver disease. PLoS One. 2016; 11: e0152549.

15. Kawatsu Y, Kitada S, Uramoto H, et al. The combination of strong expression of ZNF143 and high MIB-1 labelling index independently predicts shorter disease-specific survival in lung adenocarcinoma. Br J Cancer. 2014; 110: 2583-2592.

16. Zhang H, Wang R, Wang H, et al. Membranoproliferative glomerulonephritis in Castleman's disease: a systematic review of the literature and 2 case reports. Intern Med. 2012; 51: 1537-1542.

17. Tanaka M, Tsujimoto H, Yamamoto K, et al. Clinicopathological features of progressive renal involvement in TAFRO syndrome: A case report and literature review. Medicine (Baltimore). 2017; 96: e8216.

18. Noda-Narita S, Sumida K, Sekine A, et al. TAFRO syndrome with refractory thrombocytopenia responding to tocilizumab and romiplostim: a case report. CEN Case Rep. 2018; 7: 162-168.

19. Ozeki T, Tsuji M, Yamamoto J et al. Thrombotic microangiopathy on kidney biopsy in a patient with TAFRO syndrome. CEN Case Rep. 2018 (in press).

20. Matsumura N. Distribution of interleukin-6 in human proliferative glomerulonephritides. J Nara Med. Ass. 1992; 43, 284-296 (in Japanese).

21. Fukatsu A, Matsuo S, Tamai H et al. Distribution of interleukin-6 in normal and diseased human kidney. Lab Invest. 1991; 65: 61-66.

22. Coleman DL, Ruef C. Interleukin-6: an autocrine regulator of mesangial cell growth. Kidney Int. 1992; 41: 604-606.

23. Audia S, Mahévas M, Samson M, et al. Pathogenesis of immune thrombocytopenia. Autoimmun Rev. 2017; 16: 620-632.

24. Fujiwara S, Mochinaga H, Nakata H, et al. Successful treatment of TAFRO syndrome, a variant type of multicentric Castleman disease with thrombotic microangiopathy, with anti-IL-6 receptor antibody and steroids. Int J Hematol. 2016; 103: 718-23.

25. Terasaki Y, Ikushima S, Matsui S, et al. Comparison of clinical and pathological features of lung lesions of systemic IgG4-related disease and idiopathic multicentric Castleman's disease. Histopathology. 2017; 70: 1114-1124.

FIGURE LEGENDS

Figure 1. Kidney lesions in PC-type iMCD with TAFRO. A: The glomeruli showed lobular architecture with increasing numbers of mesangial cells and mesangial matrix (PAM staining, x200). B: Double contouring was observed (PAM staining, x1,000). C: Positivity for proliferated mesangial cells was seen (IL-6 immunostaining, x400).

Figure 2. Bone marrow lesions in iMCD with TAFRO. A: Hypercellular marrow with trabecular bone thickening, but no pronounced fibrosis (H&E staining, x100). B: Clusters of morphologically abnormal megakaryocytes showing bizarre nuclear shapes, separated nuclear shapes, hyposegmented nuclei, and hyperchromatic nuclei (H&E staining, x200).

Figure 3. Lung lesions in PC-type of iMCD without TAFRO. A: Peribronchial and periarterial chronic inflammation accompanied by the formation of LF were observed (H&E staining, x12.5). Inset: Dense plasma cell infiltration without fibrosis was observed in the alveolar septum (H&E staining, x400). B: Peribronchial and periarterial chronic inflammation were fused, and nodular lesions with lymphocyte aggregates were formed (H&E staining, x12.5).

Fig. 1

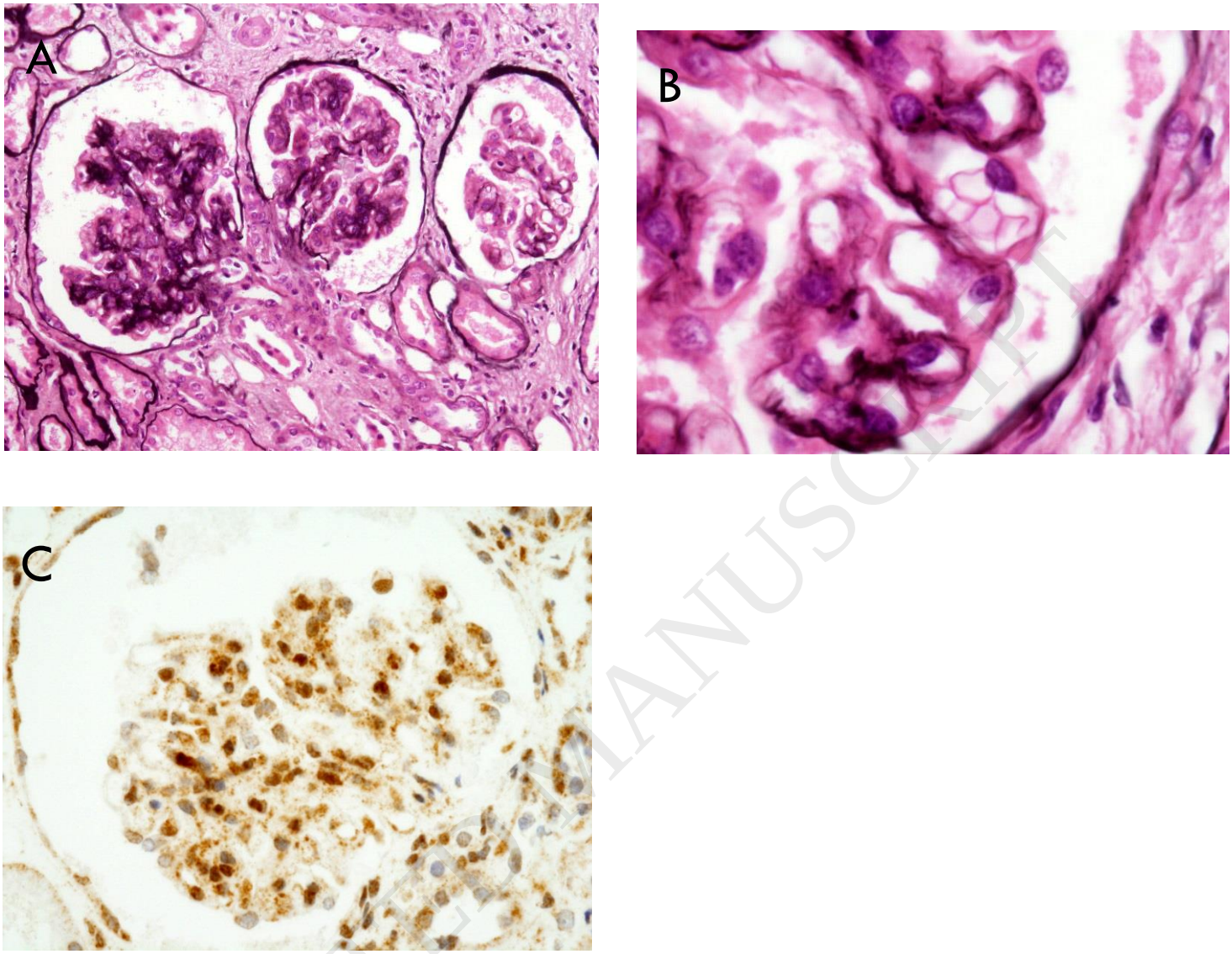

Fig. 2

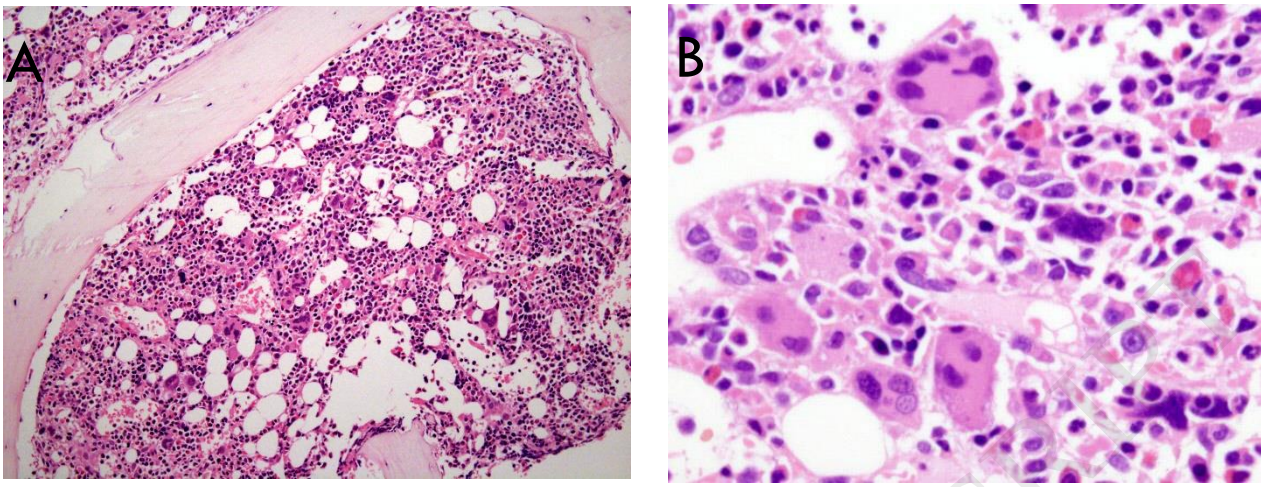

Fig. 3

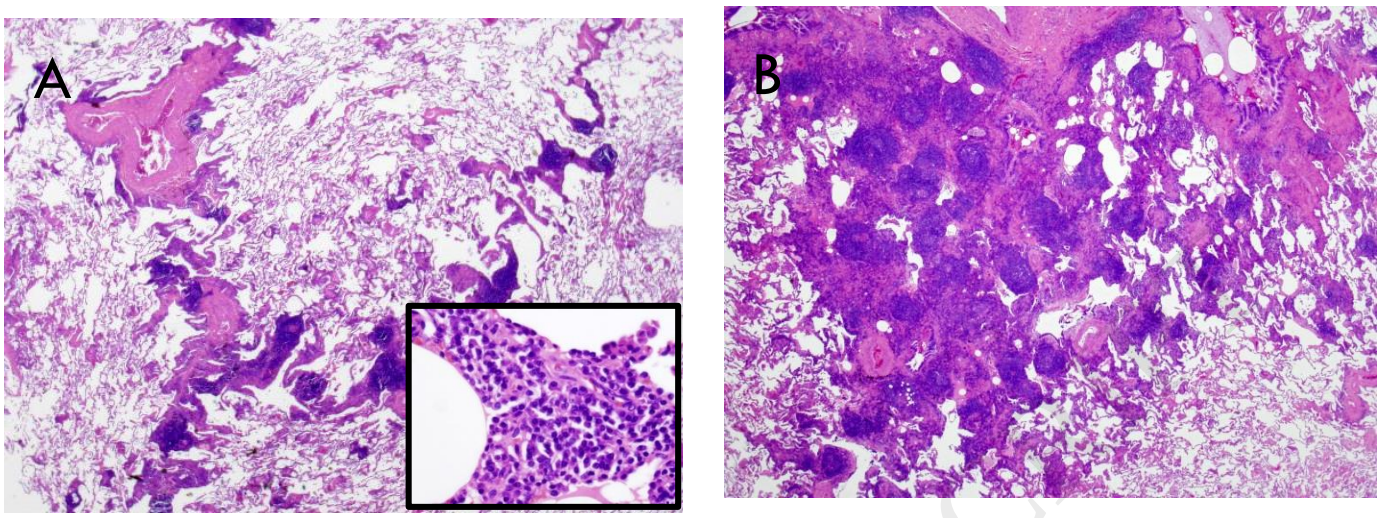

Table 1 Summarized findings of extranodal lesions

		TAFRO		non-TAFRO	
		(n = 21)		(n =9)	
Kidney		2 (PC = 1, mixed = 1)		0	
Bone marrow		14 (PC = 1, mixed = 13)		3 (PC = 2, mixed = 1)	
Lung		0		5 (PC = 5)	
Skin		3 (mixed = 2)		1 (mixed = 1)	
Thymus		2 (mixed = 2)		0	
PC, plasmacytic.					